

SENSOR Occupational Lung Disease Bulletin

A project of the Massachusetts Department of Public Health's Occupational Health Surveillance Program, the Massachusetts Thoracic Society, and the Massachusetts Allergy Society

Massachusetts Department of Public Health, Occupational Health Surveillance Program, 6th floor, 250 Washington Street, Boston, MA 02108, Tel: (617) 624-5632, Fax: (617) 624-5696

April 1997

Dear Physicians,

In the evaluation of the Bulletin conducted last summer, many of you indicated that you would like us to provide interesting case studies illustrating the difficulties in diagnosing occupational lung diseases. This month we present a case study written by two occupational medicine residents from Harvard School of Public Health describing asbestosis in a retired carpenter.

As many as 10,000 workers employed in Massachusetts shipyards during the 1950's and 1960's may have been exposed to asbestos. Other industries in the state with potential asbestos exposures include construction, plumbing, textile manufacturing, and asbestos abatement.

Since 1992, SENSOR has received 122 reports of asbestosis in Massachusetts. Because the lag time between initial asbestos exposure and the onset of disease can be as long as 40 years, the number of individuals with asbestos related diseases continues to grow each year despite the reduction in asbestos exposures in recent years. It is estimated that a minimum of 3600 Massachusetts workers will develop asbestos related lung diseases between 1991 and 2010. It is important that physicians continue to recognize the health problems associated with asbestos exposure and to understand the challenges in diagnosing asbestos related diseases.

Sincerely,
Catharine M. Tumpowsky, MPH
Occupational Lung Disease Surveillance Project

Rapidly Progressing Pulmonary Fibrosis in a Retired Shipyard Worker

E.V. Moy, MD, MPH and Arvin Chin, MD, MPH

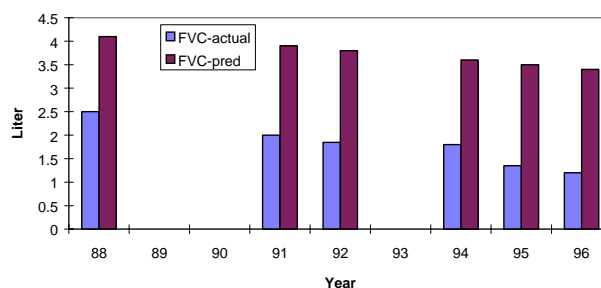
A 70 year old male carpenter retired in 1988 at the age of 62. Based on the findings of diffuse interstitial fibrosis and pleural plaques found on a screening chest x-ray, and his history of direct asbestos exposure, his physician raised concerns about asbestosis. The patient had worked in various shipyards for the previous 40 years from the 1950's through the 1980's. His work renovating and building ships placed him in direct contact with asbestos. Although the patient recalled working in clouds of airborne asbestos dust, he reported never having worn respiratory protection equipment. He had no other known occupational exposures. He

smoked cigars in his 20's on rare occasions, but had never smoked cigarettes.

After his retirement, the patient developed mild adult-onset diabetes mellitus but was otherwise healthy. He continued to lead an active and normal life dividing his time between Massachusetts and Florida. Not only was he able to maintain the lawns on his properties, but he also continued to take brisk daily walks. In 1994, the patient noted an increase of exertional dyspnea during his half-mile walks. In 1995, he experienced some difficulty while mowing his lawn. By 1996, his exercise tolerance changed from being able to actively walk and climb stairs to experiencing shortness of breath after walking a few blocks or climbing less than one flight of stairs. Mowing his lawn became extremely difficult.

In addition to the increase in symptoms, the patient was noted to have a rapidly declining Forced Vital Capacity (FVC) (see graph below). From 1988 through 1996, his Diffusion Capacity (DLCO) also decreased from 23.15 ml/min./mmHg to 14.03 ml/min./mmHg. His arterial blood gas in 1996 was pH = 7.39, pCO₂ = 45 and pO₂ = 66. At rest, his room air oxygen saturation was 92% but after walking 3 minutes, his room air oxygen saturation declined to 88%.

Actual and Predicted Pre-Bronchodilator FVC Over Time 1988-96



REPORT FEBRUARY AND MARCH CASES NOW

By April 30th, report all occupational lung disease cases seen for the first time in February and March 1997. If you have NOT seen any cases, it is not necessary to return the report form.

His chest x-rays showed mild progression of interstitial fibrosis from 1988 to 1992 and more rapid progression from 1992 to 1996. A chest CT showed evidence of

continued on other side

interstitial fibrosis and circumscribed pleural fibrosis (plaque).

Asbestos is a mineral made of hydrated fibrous silicates. Its physical properties, including high tensile strength and acid heat resistance, make it an important manufacturing material. From 1940 to 1979, over 27 million workers were exposed to asbestos in the United States. The spectrum of pulmonary diseases associated with asbestos includes bronchogenic cancer, mesothelioma, pleural plaques, and asbestosis (characterized by interstitial fibrosis). As a result of the increased recognition of the hazardous nature of asbestos, there is at present less exposure to asbestos in the workplace and in the environment. Although the annual production of asbestos in the United States has decreased since the 1970s as a result of stricter regulatory standards and product liability litigation related to its health effects, the use of asbestos is on the rise in developing countries.

Of the non-malignant diseases, pleural plaques are relatively common among asbestos exposed workers and can be readily diagnosed on a chest x-ray. On the other hand, asbestosis is less common and results in greater decline in pulmonary function. The diagnosis of asbestosis cannot be made solely on the grounds of interstitial fibrosis on a chest x-ray, because many conditions result in the same end-organ changes.

The standard for diagnosis of asbestosis is the presence of one or more asbestos bodies in lung tissue with interstitial and peribronchiolar fibrosis. Biopsies, however, are not often obtained. The clinical diagnosis of asbestosis is based on an appropriate exposure history, a long latency period of 15 or more years, and other supportive signs of asbestos exposure such as the radiographic presence of linear opacities and pleural plaques and lung function tests which may reveal a restrictive defect, mixed restrictive-obstructive defect or an obstructive defect.

The evaluating physician should take a careful sequential history of all occupational exposures. Asbestosis is associated both with the magnitude and the duration of exposure to inhaled asbestos. Prolonged direct or indirect occupational contact provides a strong indication of high exposure. There is no evidence that casual or background urban exposures, which can occur in the general population, are likely to cause asbestosis.

In this patient, the exposures were both prolonged and direct. A diagnosis of asbestosis is suggested based on this patient's occupation and exposure histories, linear opacities on chest x-ray, and pleural plaques. However, the unusually rapid progression of interstitial fibrosis raises the question of a secondary cause for the interstitial fibrotic process. Although an open lung or

transbronchial biopsy would be helpful in identifying a secondary process, the patient's low pulmonary reserve precluded such a procedure.

Besides asbestos, specific known causes of interstitial inflammatory lung disease include: drugs (antibiotics) and chemotherapeutic agents, radiation, aspiration pneumonia, and post-Adult Respiratory Distress Syndrome and other occupational exposures, such as silica (rounded opacities), mixed dust (silica and asbestos) pneumonitis and farmer's lung (hypersensitivity pneumonitis). These causes should be readily apparent from the history.

Some of the less obvious causes include collagen vascular diseases, pulmonary hemorrhage syndromes, lymphocytic infiltrative disorders, inherited diseases, gastrointestinal/liver diseases and Graft vs. host disease. In addition, there is the general classification of idiopathic pulmonary fibrosis (usual interstitial pneumonitis), a term that is invoked when a cause cannot be determined.

The identification of these other diseases is important because therapy and prognosis differ from that for asbestosis. Some of the idiopathic diseases listed above may respond to corticosteroids and responses to therapy may also provide diagnostic clues.

Hence, this patient meets the criteria for a diagnosis of asbestosis with rapid acceleration of the disease or asbestosis with superimposed usual interstitial pneumonitis.

References for this article are available on request by calling Catharine Tumpowsky at 617-624-5637.

Number of Lung Disease Cases Reported to MA SENSOR, March 1992-January 1997

	December 1996	January 1997	Total to Date (3/92-1/97)
Asthma	35	14	460
Silicosis	0	0	12
Asbestosis	0	0	122
Chemical Pneumonitis	0	0	15
Total Number of Lung Disease Reports	35	14	609